



PATIENT

Khloe Alluisi

SPECIES

Canine

BREED

Yorkie

SEX

Female Spayed

AGE

2.5.14

WEIGHT

6.8lbs

PRESENTING CLINICAL SIGNS

History: Recheck echo. Persistent systolic click, L sided. Monitoring.
 -Pertinent abnormal PE/Chem/CBC/UA Results: erythrocytosis, suspect due to stress/splenic contraction. history of tracheal collapse.

-Current medications: theophylline 50mg SID since July 2021, cytopoint injections as needed to seasonal pruritus

-Blood pressure: 118, 116, 112mmHg. (After Torb)

-Sedation used: Not required to complete full diagnostic ultrasound.

-Pertinent previous ultrasound results (4/2021 MML): Trace/mild MR, no LA or LVE.

-STAT: Not requested.

-Imaging performed by: Stephanie Warga RDCS, RVT.

ECHOCARDIOGRAM FINDINGS

2D, m-mode, color flow and doppler imaging is available. Mild diffuse thickening of mitral valve leaflets with mild prolapse into the left atrial lumen. No obvious mitral regurgitation with no left atrial dilation. Normal LV diameter with adequate myocardial function. The tricuspid valve appears normal with trace tricuspid regurgitation. Normal right atrial and ventricular diameter and morphology indicating no overt evidence of pulmonary arterial hypertension. The pulmonic and aortic valves are normal in morphology and mobility. Normal pulmonic and aortic outflow velocities with laminar flow. No obvious aortic or pulmonic insufficiency. No pericardial or pleural effusion noted. No obvious cardiac masses.

CARDIAC CHART

INTERPRETED BY

Maggie Machen Lamy,
 DVM, DACVIM
 (Cardiology)

HOSPITAL NAME

Perry Hall Animal
 Hospital

REFERRING VET

Dr. Hatzigiannakis

INVOICE

31452

DATE

6.20.23

CANINE CARDIAC PARAMETERS	MR VMAX (m/s)	TR VMAX (m/s)	LA/AO (Boon method)	LA/AO (Heart Base; Swe)	FS (%)	EF (%)	EPSS (cm)
NORMAL PARAMETER	4.5-5.5	<2.7	1.3	<1.6	28-40	40-100	<0.6
PATIENT	NA	NA	NM	1.28	40	72	NM
CANINE CARDIAC PARAMETERS	HR (BPM)	AV VMAX (m/s)	PV MAX (m/s)	BODY WEIGHT (kg)	LA 2D short axis Base view (cm)	LVIDd Avg; 2D and m-mode short axis (cm)	LVIDs Avg; 2D and m-mode short axis (cm)
NORMAL PARAMETER	50-100	0.7-1.7	0.7-1.6	BELOW	BELOW	BELOW	BELOW
PATIENT	120	1.0	0.8	3.1	1.2	1.9	1.2
*Normal chamber parameters expressed as a mean value (SD)				3	1.27 (5.3)	2.46 (2.46)	1.36 (5.5)
BODY WEIGHT DEPENDENT PARAMETERS				5	1.40 (4.5)	2.74 (5.2)	1.60 (4.7)
*Note: All measurements based upon multi-modal images and methods. An average value is reported.				10	1.50 (3.8)	3.27 (3.5)	2.06 (3.1)
				15	1.83 (2.0)	3.71 (2.4)	2.43 (2.1)
				20	2.02 (1.9)	4.14 (2.2)	2.80 (2.0)
				25	2.18 (2.4)	4.48 (2.9)	3.10 (2.5)
				30	2.33 (3.3)	4.83 (3.9)	3.39 (3.4)
				35	2.48 (4.3)	5.17 (5.0)	3.69 (4.5)
				40	2.62 (5.2)	5.48 (6.1)	3.96 (5.4)
				50	2.88 (7.1)	6.07 (8.3)	4.46 (7.4)

Adapted from June Boon, Veterinary Echocardiography, 1998
 Rishniw M and Hollis NE, J Vet Intern Med 2000; 14:429-435
 Hansson et al, Vet Rad and Ultrasound 2002
 Bonagura et al. Echocardiography: principles of interpretation, Vet Clin North Am 15:1177, 1995

INTERPRETATION OF THE FINDINGS & FURTHER RECOMMENDATIONS

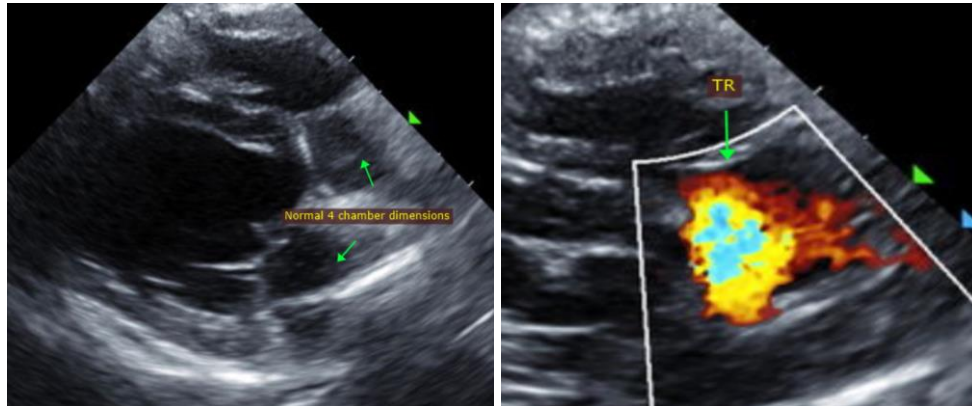
Compared to the prior study, findings are similar and essentially normal. The small mitral leak is no longer apparent, suggesting a physiologic finding. Trace TR is unchanged, and no additional issues have developed.

Given these findings, no medications are indicated. Continued assessment of progression is recommended should a persistent murmur be noted in the future. Omega fatty acid supplementation and mild salt restriction may be of some long-term benefit. Monitor for development of a cough, labored breathing, exercise intolerance or collapse episodes.

No cardiac contraindication for general anesthesia prior to chamber enlargement.

Recommend a recheck echocardiogram should a consistent murmur be noted in the future or if clinical signs arise.

IMAGES



The information and recommendations provided are based on the images presented by the referring veterinarian. No evaluation can be communicated regarding pathology that was not visible in the image/video clips provided.

Thank you for this referral. This report was generated using transcription software, and minor dictation errors may be present. If the clinical or image interpretation does not parallel your findings or if I can be of any further assistance, please contact me.

Maggie Machen Lamy, DVM
Diplomate of the American College of Veterinary Internal Medicine (Cardiology)
info@sonopath.com